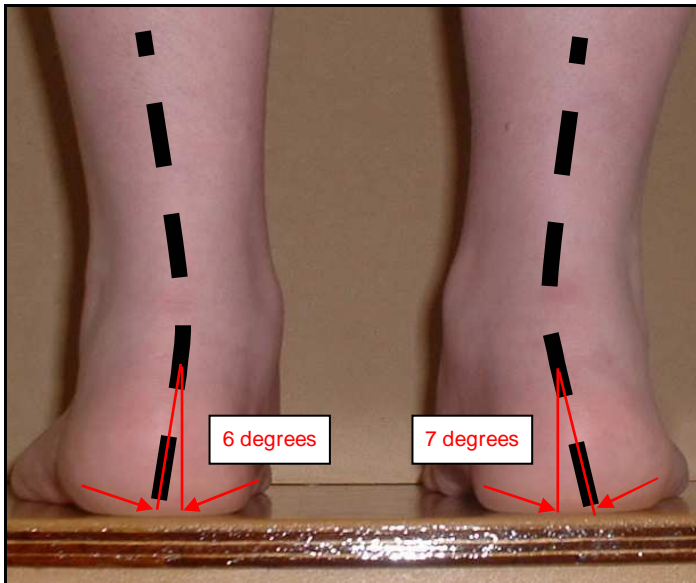




CASE STUDY- For more details contact Nick Dinsdale as above.

Name of Patient:	Male
Age:	13 years old - DOB 04.01.92
Sport / Occupation:	Student
Level of Activity:	Day to day activities
Condition:	Insufficiency of Medial Longitudinal Arches & Low Level Achilles Tendinosis

BEFORE fitting orthotics – March 2005



History:

The above patient first contacted me in July 2004 regarding foot and ankle discomfort. The patient was examined and soft orthotics were prescribed. The patient responded very successfully. The patient then contacted me again in March 2005 with similar problems. On examination it was discovered that the original soft orthotics had deteriorated and flattened, offering much reduced support and control.

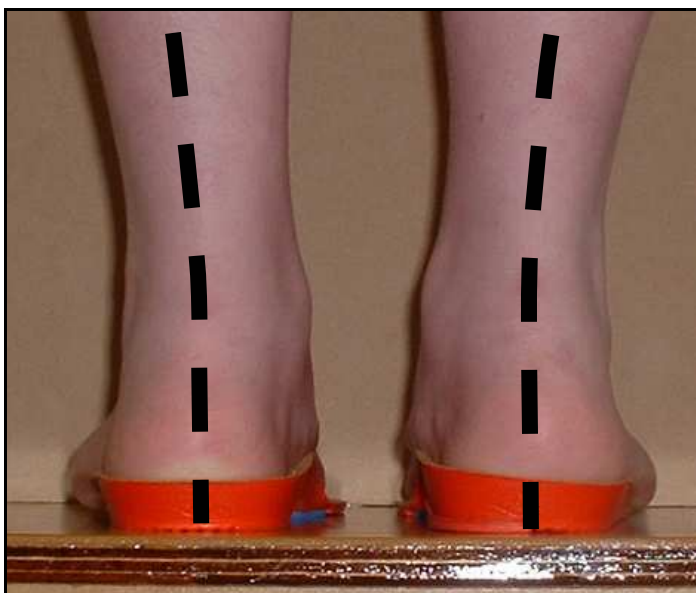
Symptoms reported by patient:

Pain on the lateral aspect of both ankles / feet, with the **right** foot worse than the left. Soreness in the Achilles tendons, **right** worse than left.

Examination & Aetiology:

- Bilateral excessive subtalar joint Pronation of **6° to 7°** (this is when the feet roll inwards). This adversely affects the biomechanics of the lower limbs placing undue stress on the feet and structures.
- Tenderness of Achilles tendons with slight thickening.
- Tight calf / Achilles complex, with poor lunge test results.
 R = 50mm, L = 65mm.

AFTER fitting Vasyli custom soft orthotics – March 2005



Agreed Treatment Plan:

Restore correct biomechanics

A pair of customised soft orthotics were fitted, with a higher density than previously used, to provide firmer support with greater durability and longer service life. These will improve the biomechanics of the lower limb by reducing excess pronation of the subtalar joint and controlling internal rotation of the legs. By doing this, it reduces the amount of abnormal stress placed on the joints of the feet and ankles and the associated soft tissue structures.

Subtalar Joint Correction factor.

Right = **7** degrees
 Left = **6** degrees

Restore Dorsi-flexion

Specific exercises were prescribed for stretching the Calf / Achilles complex (L & R) to improve flexibility and ROM of the ankle joints.

The patient was given clear and precise instructions on how to perform the exercises, correct frequency and durations. The guidelines provided are in line with current research methods and practice.

Outcome / Patient satisfaction:

As a result of this treatment my son has stopped complaining of constant pain. The exercises prescribed are simple and short enough for a 13 year old lad to stick to. July 2004, prior to the initial treatment he went on a 9 mile walk and returned in terrible pain. I can now see a vast improvement in his mobility and it has had a positive effect on his self confidence with regards to physical activity both socially and at school.